

## Case Report

# Diagnosis and management of acute acalculous cholecystitis in an outpatient: a case report

Maria Dass Scott Arockia Singh<sup>1\*</sup>, Meethala Peedikayil Anish Kumar<sup>2</sup>

<sup>1</sup>Department of General and Laparoscopic Surgery, <sup>2</sup>Department of Internal Medicine, Badr Al Samaa Hospitals, Salalah, Oman

**Received:** 12 February 2019

**Accepted:** 09 April 2019

### \*Correspondence:

Dr. Maria Dass Scott Arockia Singh,  
E-mail: [leandrascott@gmail.com](mailto:leandrascott@gmail.com)

**Copyright:** © the author(s), publisher and licensee Medip Academy. This is an open-access article distributed under the terms of the Creative Commons Attribution Non-Commercial License, which permits unrestricted non-commercial use, distribution, and reproduction in any medium, provided the original work is properly cited.

## ABSTRACT

Acute acalculous cholecystitis (AAC) is defined as acute necrotic inflammation of the gall bladder without stone disease. It commonly occurs in ICU patients associated with major trauma, burns, multiorgan failure patients, post major surgery, end stage malignancies, severe sepsis. Here we present a case of acute acalculous cholecystitis with gangrenous formation in a middle-aged outpatient without any prior illness. He was a hypertensive on medications came with complains of abdominal pain. Clinical examination and ultrasound revealed features suggestive of infective acalculous gall bladder disease. Emergency laparoscopic subtotal cholecystectomy done, discharged in a healthy state on 3<sup>rd</sup> postoperative day. We present this case to raise awareness among primary care physicians of AAC in patients with acute right hypochondrial pain. Prompt diagnosis and urgent surgical management gives the best outcome in these patients.

**Keywords:** Acalculous cholecystitis, Gangrenous gall bladder, Outpatient, Hypertension, Gall bladder disease, Laparoscopic subtotal cholecystectomy

## INTRODUCTION

Acute acalculous cholecystitis (AAC) accounts for 5-10% of all cholecystitis and carries 30 % mortality rate. In 1989, a large 7 year study by Paul et al of AAC found that 75 % of the cases occur in outpatient group than sick ICU patients.<sup>1</sup> The *denovo* type presentation of AAC is not a new and has been reported previously.<sup>1</sup> The proposed etiopathogenesis for this condition in general are gall bladder ischemia, microangiopathy and reperfusion injury, subsequently with bacterial invasion, concentration and stasis of bile with inspissation in the absence of gall bladder emptying.

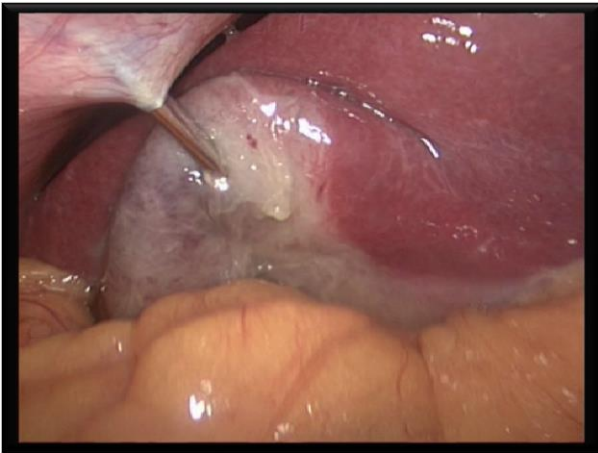
AAC diagnosis relies mainly on ultrasound findings, as follows.

- Increased gallbladder wall thickness (>3.5 mm)
- Pericholecystic fluid
- Presence of mucosal membrane sludge and
- Gallbladder distension.<sup>2</sup>

## CASE REPORT

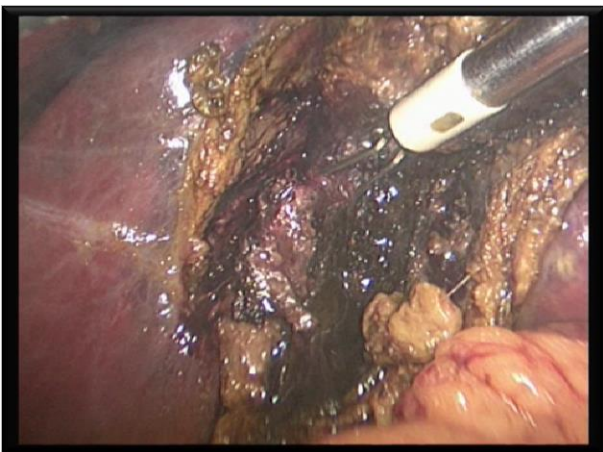
Our patient is a 44 yr old male presented to emergency room with sudden onset of abdominal pain of 10 hours duration. The pain was continuous in character and associated with vomiting. On examination BMI 28 kg/m<sup>2</sup>, hypertensive, afebrile, not icteric, severe tenderness noted in the right hypochondrium region -Murphy sign positive. Blood investigations revealed total count of 12.2 K/UL, otherwise SGOT, SGPT, ALK Phosphatase, bilirubin (direct and indirect), amylase and blood sugar were all within normal limits. Ultrasound showed thickened gall

bladder wall of 4mm size, grossly distended without stones, with minimal pericholecystic fluid collection and thick sludge. There was no intrahepatic or extrahepatic dilatation of bile ducts. Pancreas normal in size, echotexture with no ductal calcification. Sonologist also reconfirmed that there was no obvious calculous in the gall bladder or in the biliary tree. The typical presentation of right hypochondrial pain, clinical examination and ultrasound findings made us to think towards gall bladder pathology.



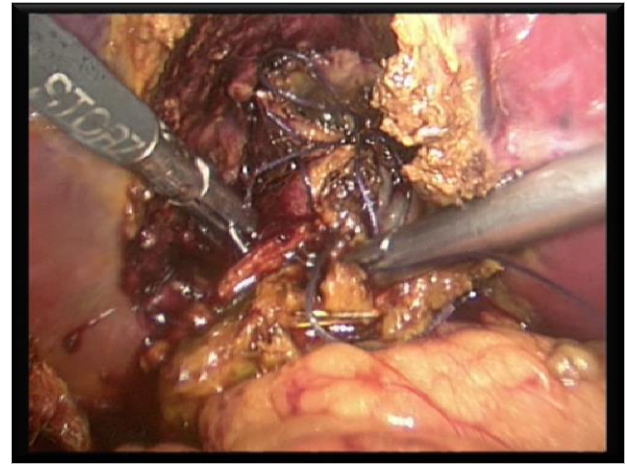
**Figure 1: Verrees needle aspiration.**

Patient prepared for emergency laparoscopic cholecystectomy. Standard 4 port technique followed, whole of gallbladder was gangrenous, covered with omentum, and fatty and oedematous Calot's triangle. Verrees needle passed directly into the distended gallbladder and aspirated about 70ml of thick black coloured bile shows that in Figure 1.



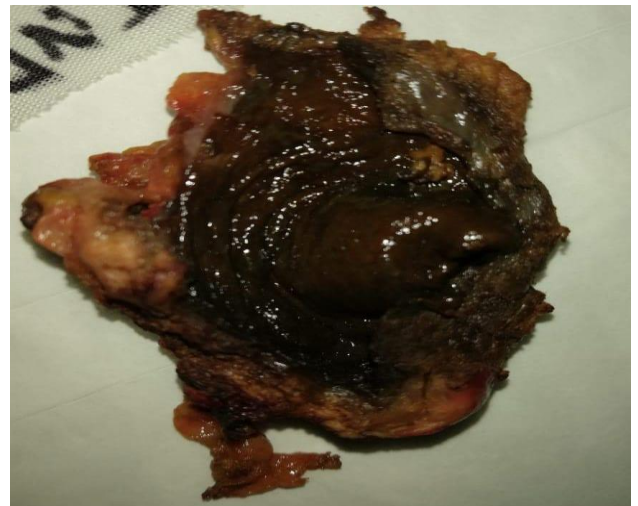**Figure 2: Gangrenous gall bladder, "Fundus First" approach.**

As the Calot's was not well delineated, we proceeded by "fundus first" technique. The gangrenous gall bladder dissected free from liver bed shows that in Figure 2.



**Figure 3: Gall bladder Stump sutured with vicryl 3 O.**

The anterior and posterior wall of the gall bladder was totally gangrenous and minimal bile in the subhepatic region. Gall bladder transected 1cm above the Hartmann's area, stump edges approximated with 3 interrupted vicryl sutures as in Figure 3.



**Figure 4: Resected gangrenous gall bladder.**

Subhepatic drain kept, thorough peritoneal lavage given and gangrenous gall bladder extracted in an endobag. The gall bladder specimen was totally gangrenous without any calculous as shown in Figure 4.

Laparoscopic subtotal cholecystectomy done and it took 2hrs and 30 minutes for us to complete the procedure. Third generation cephalosporin, injection ceftriaxone 1gm intravenously given for three days. Drain removed on 3<sup>rd</sup> postoperative with prior recheck ultrasound examination to rule out any abnormal bile collection. Patient discharged home in a stable condition and attended review clinic and remained symptom free. Biopsy reported as gangrenous gall bladder mucosa and wall with features of acute cholecystitis.

## DISCUSSION

Acalculous cholecystitis typically affects elderly males whereas gallstone disease affects young female.<sup>3</sup> Our patient is a middle-aged gentleman, hypertensive and on tablet Valsartan. He is not diabetic and no coexisting cardiovascular disease. Hypertension is the commonest coexisting disease in patients with AAC.<sup>1</sup>

Ganapathi et al considered the following criteria in their study for the diagnosis of AAC.<sup>4</sup>

- Radiological imaging studies failed to demonstrate stones or sludge in the presence of acute cholecystitis,
- Intraoperative conformation of inflamed gallbladder and absence of stones or sludge in the gallbladder, and
- Postoperative pathologic examination confirmed the diagnosis of acute cholecystitis in the absence of biliary calculi.

The cystic artery is a terminal artery, sole supply of oxygenated blood to gallbladder tissues, which explains its major susceptibility to ischemic conditions in the presence of several underlying or concomitant diseases.<sup>5</sup> Hence, sequence of ischemia, gangrene, perforation, biliary peritonitis and sepsis occur more rapidly than expected. The other causes associated with outpatient AAC are diabetes, bronchial asthma, coronary artery disease and peripheral vascular diseases.<sup>6</sup> The possible theory is microangiopathy due to hypertension leads to AAC.<sup>7</sup>

In our patient, ultrasound showed distended gallbladder, thick walled (>3.5 mm), no stones, noted thick sludge. The different diagnostic criteria for USG are GB wall thickness, pericholecystic fluid, subserosal edema, intramural gas, sloughed mucosa, sludge, and hydrops.<sup>8,9</sup>

Laparoscopic subtotal cholecystectomy is an established procedure for difficult Calot's triangle identification in gall bladder surgeries.<sup>10</sup> In our case, the calots triangle was oedematous, fatty and distorted.

The biopsy suggested the features of acute cholecystitis. Macroscopically, near total gangrenous sloughed out gall bladder, histopathology revealed bile infiltration into deeper muscle layer, epithelial degeneration, leucocyte margination of blood vessels and lymphatic dilatation. AAC patients have more pronounced necrosis and wider defects and involvement of muscle layer than patients with acute calculous cholecystitis.<sup>11</sup>

## CONCLUSION

AAC is a disease not limited to the sick intensive care patients; it affects many of outpatients as well. Delay in

diagnosis and surgical management causes devastating complications and carries high mortality rate. Moreover, it is not common illness and prudent to keep as differential diagnosis in patients with acute right hypochondrial pain.

## ACKNOWLEDGEMENTS

Authors would like to thanks the nurses in our hospital.

*Funding: No funding sources*

*Conflict of interest: None declared*

*Ethical approval: Not required*

## REFERENCES

1. Savoca PE, Longo WE, Zucker KA, McMillen MM, Modlin IM. The increasing prevalence of acalculous cholecystitis in outpatients. Results of a 7-year study. *Ann Surg.* 1990;211:4337.
2. Poddighe D, Sazonov V. Acute acalculous cholecystitis in children. *World J Gastroenterol.* 2018;24(43):4870-9.
3. Balmadrid B. Recent advances in management of acalculous cholecystitis. *F1000Res.* 2018;7.pii: F1000 Faculty Rev-1660.
4. Ganpathi IS, Diddapur RK, Eugene H, Karim M. Acute acalculous cholecystitis: challenging the myths. *HPB (Oxford).* 2007;9(2):131-4.
5. Parithivel VS, Gerst PH, Banerjee S, Parikh V, Albu E. Acute acalculous cholecystitis in young patients without predisposing factors. *Am Surg.* 1999;65(4):366-8.
6. Huffman JL, Schneker S. Acute Acalculous Cholecystitis. *A Rev Clin Gastroenterol Hepatol.* 2010;8(1):15-22.
7. Hakala T, Nuutinen PJ, Ruokonen ET, Alhava E. Microangiopathy in acute acalculous cholecystitis. *Br J Surg.* 1997; 84:1249-52.
8. Mirvis SE, Vainright JR, Nelson AW, Johnston GS, Shorr R, Rodriguez A, et al. The diagnosis of acute acalculous cholecystitis: a comparison of sonography, scintigraphy, and CT. *AJR Am J Roentgenol.* 1986;147:1171-5.
9. Boland GWL, Slater G, Lu DSK, Eisenberg P, Lee MJ, Mueller PR. Prevalence and significance of gallbladder abnormalities seen on sonography in intensive care unit patients. *AJR Am J Roentgenol.* 2000;174:973-7.
10. Supit C, Supit T, Mazni Y, Basir I. The outcome of laparoscopic subtotal cholecystectomy in difficult cases - A case series. *Int J Surg Case Rep.* 2017;41:311-4.
11. Laurila JJ, Ala-Kokko TI, Laurila PA, Saarnio J, Koivukangas V, Syrjälä H, et al. Histopathology of acute acalculous cholecystitis in critically ill patients. *Histopathology.* 2005;47(5):485-92.

**Cite this article as:** Scott ASM, Anish KMP. Diagnosis and management of acute acalculous cholecystitis in an outpatient: a case report. *Int Surg J* 2019;6:1777-9.